

# LINK Wound Healing CONGRESS 2017

POWERED BY

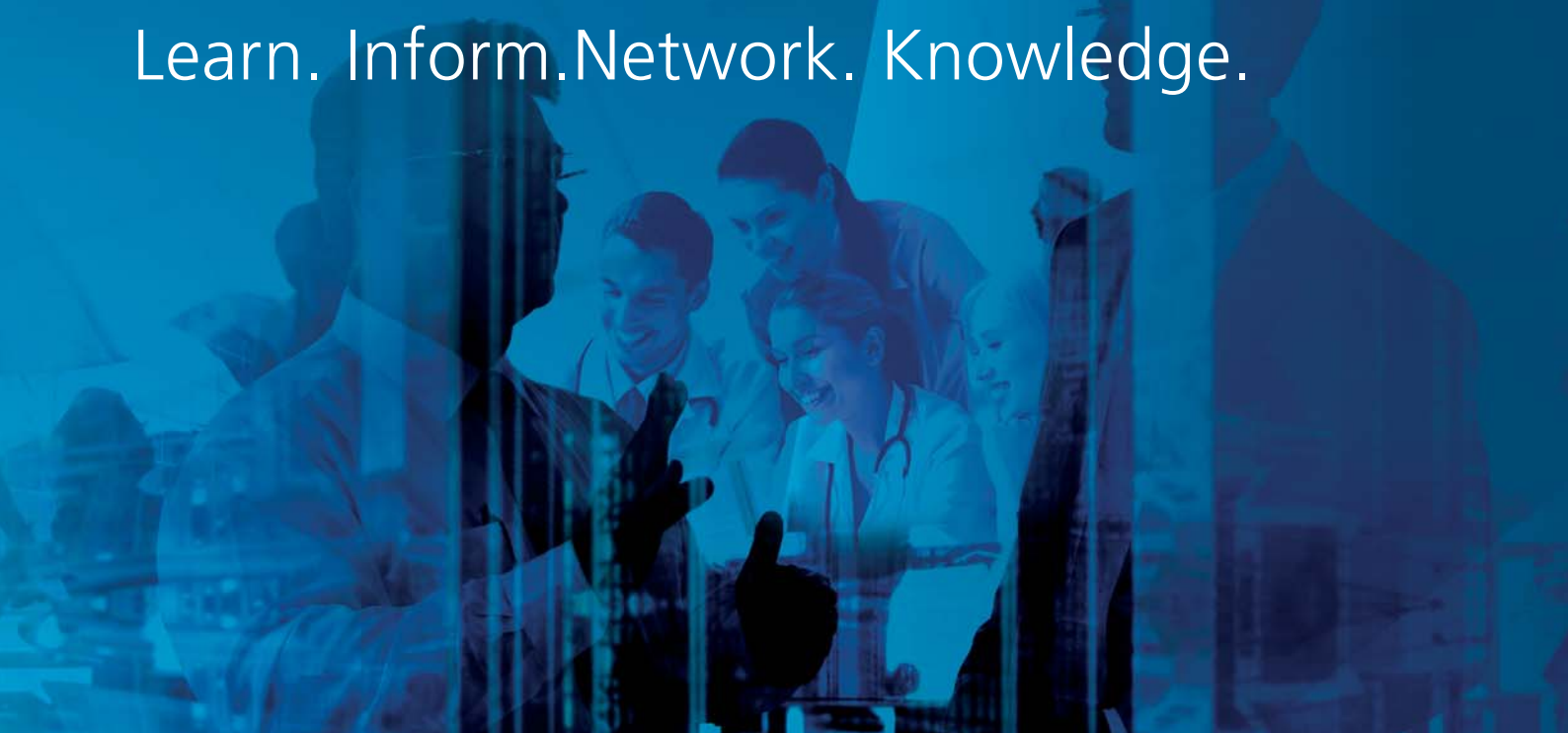


Advanced Wound Healing



# LINK

Learn. Inform. Network. Knowledge.



# Welcome

The Journal of Wound Care (JWC), the Vivano Competence Network and HydroTherapy experts are delighted to invite you to the first **LINK for Wound Healing Congress**, which will take place on the 18th and 19th September 2017 in Belfast, Northern Ireland.

This international congress represents a unique opportunity for delegates to engage with key opinion leaders from all over the world in the field of advanced wound healing including negative pressure wound therapy (NPWT). It is therefore an unparalleled chance to chart the progress in these areas that has been documented in the past few years.

In order to promote networking and knowledge exchange under the LINK umbrella (Learn, Inform, Network, Knowledge), and following the repeated success of the Vivano Congress, this international event will discuss NPWT and other innovative approaches to treat hard-to-heal wounds. This will be done in two parallel conferences: Negative Pressure Wound Therapy and Advanced Wound Healing.

We believe this is an exceptional occasion to fully understand the challenges in wound healing, and discuss the different perspectives from which these could be addressed.

We look forward to seeing you in Belfast!

With warm regards,  
JWC, Vivano Competence Network and HydroTherapy experts

## Conference information

### Monday, 18th September 2017

16:30 - 18:00 Speakers registration at the Waterfront Congress Centre  
18:30 - 21:30 Congress dinner (Dresscode: business casual/elegant)

### Tuesday, 19th September 2017

08:00 - 09:00 Registration  
09:00 - 09:10 Word of Welcome from Hartmann  
09:00 - 10:30 Plenary session  
10:30 - 17:00 NPWT Congress  
10:30 - 17:00 Advanced Wound Healing Congress

**Congress venue:** Belfast Waterfront; 2 Lanyon Place, Belfast, BT1 3WH

**Congress dinner venue:** Titanic Museum; 1 Olympic Way, Queens Road, Titanic Quarter, Belfast BT3 9EP



# Programme overview

## ADVANCED WOUND HEALING

### Hall 2A

9:00-10:00  
**Congress introduction**; *Prof. Hans Smola*  
**Clinical challenges to wound bed preparation**; *Prof. Sabine Eming*  
**How does epithelialization work?**; *Prof. Tomic-Canic*  
**Introduction of topics and key speakers**; *Prof. Hans Smola*

10:00-10:30 **Coffee Break**

10:30 - 12:00  
**Breaking the Barriers to Wound Healing** *Chairs: Sabine Eming, Hans Smola*  
**Mechanisms of HydroClean**; keynote speaker *Sabine Eming*  
**HydroTherapy: the importance of hydration in wound healing**; keynote speaker *Karen Ousey*  
**The effect of a HRWD (HydroClean) on mature biofilms in vitro**; *Matthew Malone, et al*  
**Autolytic Debridement with HydroClean: Case report**; *Hatice Kükücer*  
**Observing the performance of irrigo-ansorbent dressing (HydroClean) on adipose post surgical**; *Marguerite Nicodeme, Maxime Cheron, Virginie Fourchette, Isabelle Fromantin*  
**Avoiding surgical debridement and maintaining patient wellbeing all in one product**; *Chloe Cara*  
**Hydroresponsive dressings: a good option to manage longterm failures of chronic wounds**; *Michaela Kaiser, Alex Ochsner*

12:00 - 13:30 **Lunch break & poster viewing**

13:30 - 15:00  
**Obtaining Epithelialization** *Chairs: Marjana Tomic-Canic, Emmanuelle Candas*  
**Mechanisms of HydroTac**; keynote speaker *Hans Smola*  
**Treatment of an exposed tendon with HydroTac**; *Sharron Cole*  
**An easy way to manage superficial 2<sup>nd</sup> degree burns in children**; *F. Duteille, P. Ridet, P. Perrot*  
**Treatment of ulcers with various etiologies**; *Jacek Mikosinski*  
**HydroTherapy**  
**Wound management is everyone's concern**; keynote speaker *Emmanuelle Candas*  
**Hydrotherapy - a unique approach to treating foot ulcers in UK**; *Paul Chadwick, Samantha Haycocks*

15:00 - 15:30 **Coffee break**

15:30-17:00  
**HydroTherapy Clinical Approach**; *Chairs: Emmanuelle Candas, Tomas Kopal*  
**Evaluating unexpected clinical changes in most therapies**; keynote speaker *Tomas Kopal*  
**Hydrotherapy in the management of postoperative Diabetic Foot wounds**; *Eduard Catrina*  
**Extensive multifocal PU in a young female bedridden due to MS: a case study**; *Marcin Malka, Bartosz Ziemięcki, Agnieszka Wołowicz*  
**Clinical experience on how HRWD are used in the treatment of hard-to heal wounds**; keynote speaker *Frans Meuleneire*  
**Simplifying wound dressing selection for residential aged care nurses**; *Tabatha Rando, Ai Choo Kang, Jo Boylan, Anthony Dyer*



# Oral presentations abstracts overview

## Scientific Introduction

**Clinical challenges in wound bed preparations**, *Dr. Sabine Eming, Professor of Dermatology*

**How does epithelialization work?**, *Marjana Tomic-Canic, PhD, Professor of Dermatology*

## Breaking the Barriers to Wound Healing

**Mechanisms of HydroClean®**, *Sabine Eming*

**HydroTherapy: the importance of hydration in wound healing**, *Sabine Eming*

**The effect of a HRWD (HydroClean) on mature biofilms in vitro**, *Karen Ousey*

**Autolytic debridement with HydroClean - case report**, *Hatice Kükücer, Turkey*

**Observing the performance of irrigo-ansorbent dressing (HydroClean) on adipose post surgical**,  
*Marguerite Nicodeme, Maxime Cheron, Virginie Fourchette, Isabelle Fromantin, France*

**Avoiding surgical debridement and maintaining patient wellbeing all in one product**, *Chloe Cara, Australia*

**Hydroresponsive dressings: a good option to manage longterm failures of chronic wounds**,  
*Michaela Kaiser, Alex Ochsner, Switzerland*

## Obtaining Epithelialization

**Mechanisms of HydroTac®**, *Hans Smola*

**Treatment of an exposed tendon with HydroTac**, *Sharron Cole, United Kingdom*

**An easy way to manage superficial 2nd degree burns in children**, *F.Duteille, P.Ridel, P.Perrot, France*

**Treatment of ulcers with various etiologies**, *Jacek Mikosiński, Poland*



# HydroTherapy Clinical Approach

**Wound management is everyone's concern,** *Emanuelle Candas*

**Hydrotherapy - a unique approach to treating foot ulcers in UK,** *Paul Chadwick, Samantha Haycocks, United Kingdom*

**Evaluating unexpected clinical changes in moist therapy,** *Tomas Kopal*

**Hydrotherapy in the management of postoperative Diabetic Foot wounds,** *Eduard Catrina, Romania*

**Extensive multifocal PU in a young female bedridden due to MS: a case study,** *Marcin Malka, Bartosz Ziemiecki, Agnieszka Wołowicz, Poland*

**Clinical experience in a case series on how Hydro Responsive Wound Dressings (\*) are used in the treatment of hart-to heal wounds,** *Frans Meuleneire, Belgium*

**Simplifying wound dressing selection for residential aged care nurses,** *Tabatha Rando, Ai Choo Kang, Jo Boylan, Anthony Dyer, Australia*



# HydroTac<sup>®</sup>

Accelerated wound closure with AquaClear Gel Technology<sup>[1, 2]</sup>

HARTMANN



Going further  
for health



23.5 %  
faster  
epithelialization<sup>[\* 3]</sup>

Benefit from the advantages of HydroTac<sup>®\*\*\*</sup> now

**Fast:** 23.5 % faster epithelialization than silicone interface<sup>[\* 3]</sup>

**Active:** 3-times greater concentration of growth factors<sup>[1, 2]</sup>

**Effective:** Promotes moist wound healing environment via unique AquaClear Gel Technology<sup>[4-10]</sup>

Part of  
**HydroTherapy**  
Efficacy. And Simplicity.

[hydrotherapy.info](http://hydrotherapy.info)

\* Compared to silicone interface, in-vivo study. \*\* AquaClear Gel Technology

[1] Smola, H. (2016). Simplified treatment options require high-performance dressings – from molecular mechanisms to intelligent dressing choices. EWMA 2016. Bremen, 11-13 May, 2016. [2] Smola, H. et al. (2016). Hydrated polyurethane polymers to increase growth factor bioavailability in wound healing. HydroTherapy Symposium: A New Perspective on Wound Cleansing, Debridement and Healing. London, 3 March, 2016. [3] Smola, H. (2015). Stimulation of epithelial migration – novel material based approaches. EWMA Congress. London, 13-15 May, 2015. [4] Ousey, K. et al. (2016). HydroTherapy Made Easy. Wounds UK 12(4). [5] Knowles, D. et al. (2016). HydroTherapy® wound healing of a post amputation site. Wounds UK Annual Conference. Harrogate, 14-16 November, 2016. [6] Smola, H. et al. (2014). Hydrated polyurethane polymers to increase growth factor bioavailability in wound healing. EORS Congress. Nantes, 2-4 July, 2014. [7] Ousey, K. et al. (2016). Hydro-Responsive Wound Dressings simplify T.I.M.E. wound management framework. British Journal of Community Nursing 21 (Suppl. 12), pp. S39-S49. [8] Spruce, P. and Bullough, L. (2016). HydroTac®: case studies of use. HydroTherapy Symposium: A New Perspective on Wound Cleansing, Debridement and Healing. London, 3 March, 2016. [9] Spruce, P. et al. (2016). A case study series evaluation of HydroTac®. HydroTherapy Symposium: A New Perspective on Wound Cleansing, Debridement and Healing. London, 3 March, 2016. [10] Smola, H. et al. (2016). From material science to clinical application – a novel foam dressing for the treatment of granulating wounds. HydroTherapy Symposium: A New Perspective on Wound Cleansing, Debridement and Healing. London, 3 March.



# Clinical challenges in wound bed preparations

**Dr. Sabine Eming, Professor of Dermatology**

*Department of Dermatology, University of Cologne, Germany.*

In impaired wound healing, perturbed inflammation is a major clinical challenge. The initial inflammatory phase becomes chronic and blocking the emergence of a healthy and productive granulation tissue. The microenvironment of the wound changes. Excessive proteases destroy growth factors such as VEGF or HFG involved in tissue angiogenesis and epithelial proliferation and migration. Detailed analysis reveals that the phenotype of macrophages at the early- and late-stages of the inflammatory response are important regulators of granulation tissue formation and interleukin-4 alpha receptor-mediated profibrotic scarring. A clear understanding will help clinicians to effectively treat patients with chronic wounds particularly at the stage of wound bed preparation. Moreover, clinicians will get better insights into fibrotic scarring, a condition causing significant impairment and discomfort for patients.

# How Does Epithelialization Work?

**Marjana Tomic-Canic, PhD, Professor of Dermatology,**

*Director of the Wound Healing and Regenerative Medicine Research Program at the Department of Dermatology and Cutaneous Surgery, University of Miami Miller School of Medicine*

This presentation will focus on the pivotal role of keratinocytes in epithelialization, including cellular processes and mechanisms of their regulation during re-epithelialization and the role of growth factors in this process. Cross-talk with other cell types in the granulation tissue will be reviewed and the underlying pathology of impaired epithelialization in chronic wounds explained. Also, recent discoveries in the field as well as open issues in current therapeutic approaches will be highlighted. A comprehensive understanding of the epithelialization process will ultimately help the clinician to approach epithelial wound closure with new perspectives in their daily routines.

## Mechanisms of HydroClean®

**Dr. Sabine Eming, Professor of Dermatology**

*Department of Dermatology, University of Cologne, Germany.*

Inflammation is a major pathogenic factor underlying impaired wound healing. As a consequence, protease activities reach excessive levels which degrade growth factors and newly produced extracellular matrix. Wound healing stalls, a healthy and robust granulation tissue does not form.

Surgical debridement is recommended by numerous guidelines and expert recommendations. Yet, few patients have access in the outpatient setting. Alternative options are needed which can be used by experts and non-specialists.

We analyzed whether polymers in wound dressings can reduce protease activities to normal levels and improve the emergence of granulation tissue. Polyacrylates can block excessive protease levels by 87%. A randomized controlled trial showed that a dressings containing polyacrylates (HydroClean) was able to induce significantly more granulation tissue in venous leg ulcers compared with the control group receiving an amorphous hydrogel.

## HydroTherapy: the importance of hydration in wound healing

**Prof. Karen Ousey**

*Director, Institute of Skin Integrity and Infection Prevention, School of Human and Health Science, University of Huddersfield, UK*

This presentation will discuss the main challenges of managing hydration in a wound. The benefits of achieving a moist environment in chronic wounds (facilitating the healing process of the wound, increasing breakdown of dead tissue, reducing scar formation), as well as the key aspects of wound bed preparation, will also be identified.

It will be explained how advanced wound care products, such as HydroClean Plus and HydroTac, can relate to the TIME framework, help create a moist wound environment and optimise hydration. These outcomes will be supported by a series of case studies and clinical papers.



# The effect of a Hydro-Responsive Wound Dressing (Hydroclean®) on mature biofilms in vitro

Malone M<sup>1, 2, 3</sup>, Johani K<sup>4</sup>, Hu H<sup>4</sup>, Vickery K<sup>4</sup>

- 1) High Risk Foot Service, Liverpool Hospital, South West Sydney LHD, Sydney, Australia.
- 2) Molecular Medicine Research Group, Microbiology & Infectious Diseases, School of Medicine, Western Sydney University, Sydney, Australia
- 3) Liverpool Diabetes Collaborative Research Unit, Ingham Institute of Applied Medical Research, Sydney, Australia and the University of New South Wales, Sydney, Australia
- 4) Surgical Infection Research Group, Faculty of Medicine and Health Sciences, Macquarie University, Sydney, Australia.

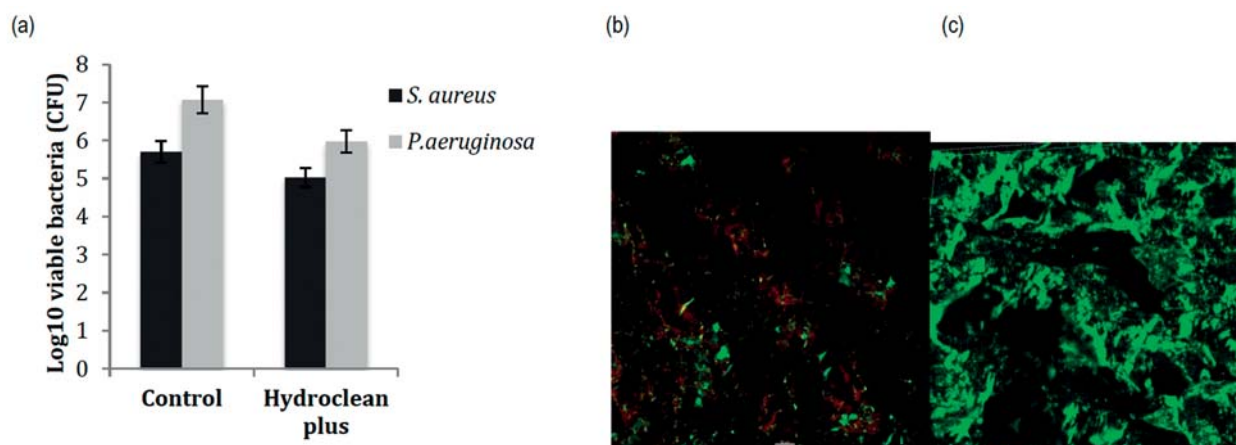
**Background:** Wound bed preparation utilizing the T.I.M.E principal is integral to removing barrier to non-healing. The presence of bacteria, either in planktonic or biofilm phenotype can aid in the chronicity of wounds and their control / removal may augment wound healing.

**Method:** 107 – 108 cells/ml of *P. aeruginosa* (ATCC 25619) and 106 *S. aureus* ATCC 25923 biofilm was grown under shear (130 r.p.m.) on polycarbonate coupons in a CDC biofilm reactor (BioSurface Technologies Corp., Bozeman, MT). Three coupons each with biofilm was incubated in the ringer's solution that was completely expelled from a Hydro-Responsive Wound Dressing (Hydroclean®, Paul Hartmann) and the dressing placed on top for 24-hour exposure time. Outcome measures were assessed for bacterial cell viability pre-and post-exposure using BaLight™ (Live/Dead Bacterial Viability Kit, 7012, Molecular Probes, Invitrogen, Carls-bad, CA, USA) with CLSM and expressed as percentage viability. Pre-and post-exposure average CFU/mL counts per coupon was expressed as Log<sub>10</sub>.

**Results:** In vitro assessment demonstrated variable efficacy against the test strains. The Hydroclean® dressing demonstrated a 0.7 Log<sub>10</sub> reduction against *S. aureus* and a 1.1 Log<sub>10</sub> reduction against *P. aeruginosa*. Live/Dead stain identified that 93% of *S. aureus* cells were still viable at 24 hours (Live – 93.2% vs Dead – 6.8%), in contrast to only 28% of *P. aeruginosa* (Live – 28% vs Dead – 72%).

**Conclusion:** These findings suggest that Hydroclean® may be safe for use in wounds with potential biofilm. Whilst not possessing an active antimicrobial release, the hydro active dressing that contains PHMB within its fibres, will not promote or enhance increased microbial loads from chronic wounds requiring autolytic debridement. The intense rinsing effects of the Hydroclean® dressing may physically disrupt the outer layers of biofilm and any planktonic microorganisms that may be absorbed and bound to the superabsorbent polyacrylate (SAP)

Figure 1 (a) Pre and post treatment of 24-hour exposure and remaining viable cells through CFU. (b) *P. aeruginosa* Live/Dead stain and (c) *S. aureus* Live/Dead stain.



# Autolytic Debridement with HydroClean®

*Hatice Küçüker*

*Tepecik Education and Research Hospital, İZMİR, Wound Care Nursing*

**Introduction:** Deterioration of texture integrity for any reasons is called a wound. The purpose in the treatment of all wounds, irrespective of type, is to heal the wounded tissue within the shortest time and before any complications emerge. The process of removing contaminated tissues that have lost their vitality and foreign substances on and around the perimeter of wounds is named debridement. The necrotic tissues in the wound prevent the normal wound healing process, and create a culture medium that is compatible for bacterial growth. Debridement plays an important part in the wound healing process; it reduces the bacterial load, enables infection control and prevention, and allows to see the wound wall and live tissues. Although surgical debridement is accepted as the fastest and the most effective debridement method, it may not be possible to apply this sometimes. One of the most frequently used debridement methods under such circumstances is autolytic debridement. Collagenase and protease, which breakdown proteins, are produced by macrophages and allow for debridement to be achieved as a result. Moist wound conditions facilitate debridement because they have the water and enzymes necessary for the elimination of dead tissues.

**Case:** M.K 28 years' old male patient. The wound site was dressed on a daily basis for the patient on whom fasciotomy was applied in the form of a skin incision as a consequence of the compartment syndrome that developed in the thigh of the left leg as associated with a gun wound. Evisceration started to develop on the 3rd day on the top side of the wound, the lips of which were sutured following limited debridement in the operating room on the 12th day. HydroClean application was planned for autolytic debridement, flushing and absorption purposes on the wound of 8\*12cm in diameter, with running, necrotic areas and 1 cm cavity. The wound was flushed with Physiological Saline. A cream with barrier features was applied on the surrounding tissues for protection purposes. HydroClean was placed in the wound bed and fixation was ensured by a covering pad. This procedure was repeated on a daily basis for 6 days. Whitening was observed on the wound perimeter during this period. The area that was thought to be maceration was eliminated with the vaporization of the ringer solution when the treatment was ended. The patient did not complain of any pain during dressing changes. Starting with the 7th day, it was observed that the cavity area in the wound was filled in, the wound diameter receded to 10\*6cm, the exudate was reduced, the necrotic tissues disappeared, granulation was increased, and epithelization started , and the treatment was ended. Wound care was continued with wound dressing with moisturizing and absorbent features.

**Conclusion:** The necrotic tissues and uncontrolled exudate in the wound prevent wound healing and offer an environment compatible for bacterial reproduction. The use of a product that accelerates wound healing with effective wound cleaning and debridement features, fights with bacteria, is absorbent, increases granulation and stimulates epithelization is an important and effective approach in wound treatment. The time and costs savings in the application of the product on the patient are also very important.

Autolytic debridement is a very effective an advantageous method in necrotic and exudative ulcers because it is painless and has a selective character.

## References:

- (Yavuz 2003), (Thomas and Jones, 2001)
- (Singhal et.al, 2001), (Dowsett), (Edwards, 2005)
- (Güneş and Eşer, 2006)

# Observing the performance of irrigo-absorbent dressing (HydroClean®) on adipose tissues on post-surgical wounds.

*Marguerite Nicodeme, Maxime Cheron, Virginie Fourchette, Isabelle Fromantin*

*Institut Curie, Paris, France*

Patients who have been operated on breast reconstruction (DIEP, PAM), on a mastectomy or a hip disarticulation have sometimes wound healing disorders and emerging necrosis. Once the necrosis is demarcated, a debridement can be achieved. The wound bed is often made of partially adipose tissues, less well vascularized whose granulation is difficult.

**Aim:** Observing the irrigo-absorbent dressing efficiency, during granulation wound, partially made of adipose tissues, in order to improve thoughts and care related to these wounds.

**Methods:** Observing the development of 6 post-surgical wounds treated with irrigo-absorbent dressing, compared to 6 similar wounds with non-standardized care (retrospective analysis) included hydrofiber, hydrocellular, NPWT, oxygen-therapy.

**Results:** 12 womens, aged from 21 to 68 years, with a BMI average 30 [15 à 52] participated. They had wounds after cancer surgery: mastectomy, reconstructive surgery (e.g: deep inferior epigastric perforator) and 1 hip disarticulation. Granulation tissue was obtained in 10 days [8-14] with an Irrigo-absorbent and in 17 days [5-23] for other group. Patients had a BMI significantly higher in the first group. The second group present others delay factors of wound healing.

**Conclusion:** These positive results suggest different questions : does the dressing normalize the wound environment, regulating the acid-base balance? Does it have an impact on less vascularized tissues angiogenesis? Is there a link between acid-basic balance and fibroblasts activity change? These first encouraging results would deserve to be faced on a larger patient's panel.

**Clinical relevance:** Irrigo-absorbent dressing seems especially effective on wounds with adipose tissue.

## References:

- Atkin L, Ousey K. Wound bed preparation: A novel approach using HydroTherapy. Br J Community Nurs. 2016 Dec;21(Sup12):S23-S28
- Colegrave M1, Rippon MG2, Richardson C3. The effect of Ringer's solution within a dressing to elicit pain relief. J Wound Care. 2016 Apr;25(4):184, 186-8, 190
- Nicodeme M, Rollot F, Fromantin I. Neutral and impregnated dressings and products. Soins. 2016 Jan-Feb;(802):36-7 (French)

# Avoiding Surgical Debridement and Maintaining Patient Wellbeing all in one product!

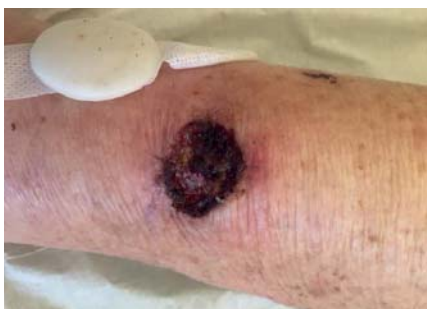*Mrs Chloe Cara*

*Melbourne, Australia*

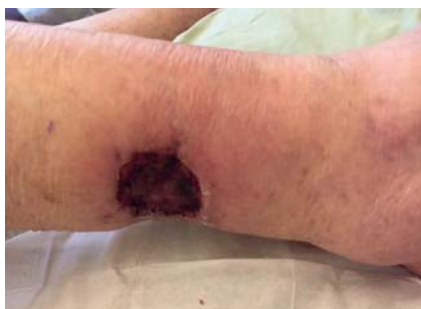**Introduction:** Venous leg ulcers (VLU) are the most serious complication of venous hypertension. Venous origin approximately makes up 80-90% of wounds (MacGregor, 2013). MacGregor, 2013 and Kapp, Miller and Donohue 2013, suggest that between 1-2% of the population will develop a VLU at some time in their life, due to insufficiencies in the veins, skin condition changes, trauma, renal impairment and cardiac disease, all in which result in an accumulation of blood in the venous system. Velnar, Bailey and Smrkolj (2009) assert that VLU have a high rate of recurrence (69%, four or more episodes) and are considered to be a major health care problem. The estimated annual cost of treatment according to Kapp, et. al., 2013 is approximately \$400 to \$500 million annually. Practitioners strive to find a dressing that's efficient, increases wound healing rates and optimises patient's holistic care. The below case will discuss the use of HydroClean plus a dressing that did just that.

**Case description:** Mrs B, 88 year old female, scratched her leg, posteriorally putting on her class 2 compression hosiery. Mrs B is on warfarin therapy, and thought with using povidone iodine and first aid dressings, the scratch would heal. After four days, Mrs B was concerned the scratch was getting bigger, therefore attended a review. Upon review the scratch, was not healing as Mrs B usually would, so a punch biopsy was recommended. The punch biopsy revealed atypical carincoma with malignancy, and needed 3cm margins. Anteriorally, another suspicious lesion was removed, with the same result. Mrs B was admitted for a surgical skin graft, which was left post operatively for 10 days, resulting in 100% necrosis and failure of the skin graft. These areas were excruciating for Mrs B. Targin, Panadol Osteo and Endone were not taking away her pain. She was confused, and not sleeping.

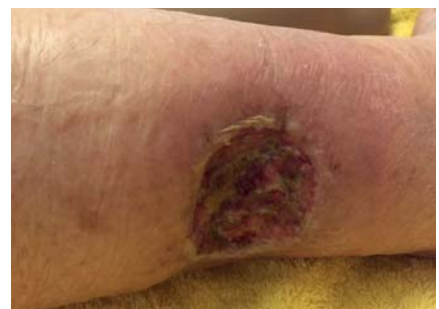**Discussion/Conclusion:** Being unable to conservatively sharp debride due to pain, autolytic debridement using HydroClean Plus was utilised. In the core of HydroClean Plus, bacteria are killed by the antiseptic polyhexanide (polyhexamethylene biguanide or PHMB) and remain encased in there. Resulting in autolytic debridement for up to 72 hours. As per the photos below, the results were outstanding in 10 days. The treatment meant the patient could be independent, pain free within her own home, with 2-3 day dressing changes. This was cost effective for the patient and the practitioners.



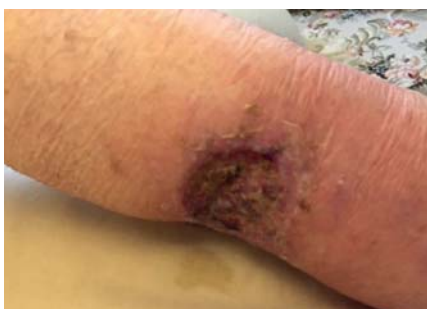*Anterior Wound Initial*



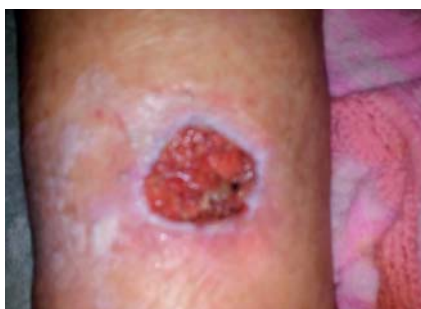*Posterior Wound Initial*



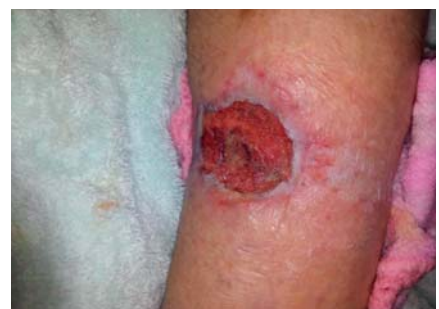*3 Days Anterior Wound*



*3 Days Posterior Wound*



*2 weeks Anterior Wound*



*2 weeks Posterior Wound*

**Clinical relevance:** Mrs B avoided another hospital admission for surgical debridement, and avoided the need to cease her warfarin therapy again, altering her INR readings. Overall, HydroClean plus enabled a cost effective management plan that addressed both intrinsic and extrinsic factors in Mrs B's management.

**Acknowledgements:** Do I acknowledge Paul HARTMANN for the opportunity of presenting a holistic patient centred care approach to wound care and sharing with you all in Belfast.

**Conflict of Interest:** There is no conflict of interest that needs to be noted. As treatment was commenced from best clinical judgement, not from any endorsements.

**References:** Hartmann (2017). Management of chronic wounds. Retrieved, from, URL: [www.hartmann.info/en-AU/medical-knowledge/wound-management/Management-of-chronic-wounds](http://www.hartmann.info/en-AU/medical-knowledge/wound-management/Management-of-chronic-wounds) / Kapp,S., Miller, C. & Donohue, L. (2013). The clinical effectiveness of two compression stocking treatments on venous leg ulcer reoccurrence: A randomised control trial. *The International Journal of Lower Extremity Wounds*. 12(3): 189-98 / MacGregor, L. (2013). Principles of compression in venous disease: A practitioner's guides to treatment and prevention of venous leg ulcers; *Wounds International*. / Velnar, T., Bailey, T. & Smrkolj, V. (2009). The wound healing process: An overview of the cellular and molecular mechanisms. 37(5): 1528-40

## Hydroresponsive dressings - a good option to manage longterm failures of chronic wounds

*Michaela Kaiser (wound expert), Alex Ochsner (MD, consultant surgeon)*

*Wound outpatient clinic, Surgical Departement, Spital Limmattal, Urdorferstrasse 100 CH-8952 Schlieren, Switzerland*

**Aim:** Treatment of chronic wounds can still be a challenging task. The longterm failure of wound healing often results in considerable patients anxiety and despair, a burden of different woundmaterials, painful dressings and frustration of the patient and the health worker. During our experience of many years in wound management a number of multimorbide patients with chronic non healing wounds, sometimes for more than a year, were referred to our institution. We present 5 cases of successful woundhealing in difficult chronic wounds with the use of hydroresponsive dressings.

**Methods:** The in- and outpatient documents of 5 patients referred to our institution with exceptional longstanding non healing wounds and finally successful treatment by the use of hydroresponsive dressings were analyzed. We looked at wound location and type, systemic factors inhibiting woundhealing, type of prior wound dressings and time to heal under hydroresponsive dressing.

**Results:** We treated two women and three men with an average of 77 years, two of them suffering on severe periphere arterial disease, 4 of them with dermatologic diagnosis and high dose steroid-therapy. Non healing time in all cases over a half year, in two cases more than 2 years. The wounds were covered by hydroclean therapy, in two cases we continued with hydrotac until woundclosure was observed. In all cases, no debridement was undertaken because of aetiology or pain. The average healing time represents 1- 3.5 months.

**Conclusion:** In chronic and non healing wounds, modern hydroresponsive dressings are an option, for effective and successful wound treatment, even when debridement isn't possible. As a prerequisite for success systemic factors inhibiting wound healing, like vascular disease, diabetes and malnutrition must be diagnosed and optimized.

**Clinical relevance:** Expert opinion on the treatment of difficult chronic wounds

**Conflict of Interest:** Our Institution is a Reference-Center of IVF-Hartmann AG

# Mechanisms of HydroTac®

*Dr. Hans Smola, Professor of Dermatology*

*Department of Dermatology, University of Cologne, Germany.*

In many patients, epithelialization becomes the rate limiting step in the healing process. From our perspective, there is little clinicians can do to speed epithelialization apart from surgery. Topically applied growth factors would be best. From our review there is no business case for growth factors due to excessively high development cost (including clinical trials), risk and safety concerns. So, our approach was to focus on boosting growth factors that are endogenously produced. We investigated hydrated polyurethanes. From complex fluids, they absorb preferentially water and low molecular weight substances. Proteins enter the polymers much slower so that their concentration increases relatively in the outside fluid compartment. We looked at HGF found a 3-fold increase in relative concentration which favored faster epithelialization in scratch assays. In a pig study, split thickness donor sites had faster epithelial tongue migration with these hydrated polyurethanes compared with silicone interface dressings.

# Treatment of an exposed tendon with HydroTac

*Sharon Cole, Vascular Clinical Nurse Specialist*

*Black Country Vascular Centre, Russells Hall Hospital, The Dudley Group NHS Foundation Trust, United Kingdom*

**Introduction:** Open wounds with an exposed tendon situated on the lower leg present a significant challenge to the clinician in order that they may treat and obtain a positive healing outcome. Of great importance is that the location of the wound will impede mobility of the tendon and may well lead to chronic inflammation that in turn hinders wound closure. Tendons are nourished by blood vessels and diffusion of nutrients from synovial fluid, exposure of this structure to air will cause desiccation and subsequent tissue necrosis and infection (Geiger et al., 2016). These types of wounds therefore require a treatment regimen that will promote the development of granulation tissue and ultimately enable reepithelialisation and coverage of the exposed tendon as rapidly as possible.

**Case description:** This Case Study shows how HydroTac® successfully treated a patient with a painful lower extremity chronic wound and exposed tendon. In spite of exudate levels being moderate/high, the primary clinical challenge was desiccation prevention, whilst maintaining optimum moisture balance enabling wound bed preparation. The patient also suffered pain both at and between dressing changes, this impacted detrimentally the patients Quality of Life – hence atraumatic removal was of high importance to the patient. After just 3 days of treatment with HydroTac® the wound showed an improvement in the appearance of the tendons and wound bed. Subsequent dressing changes (over the next few months) demonstrated an improvement in the tendons and importantly a significant amount of granulation tissue was formed such that eventually the tendons were completely rec-covered in healthy wound tissue. Furthermore, HydroTac® was soothing and comforting to the patient thus reducing the need for opiate analgesia, improving patient confidence and aiding compliance with treatment.

**Discussion/Conclusion:** HydroTac® provided a combination of absorption and moisture donation, thus desiccation and necrosis damage to tendons was prevented and the wound bed was kept in a balanced, moist environment enabling optimisation of healing whilst reducing pain and increasing patient compliance.

**Clinical relevance:** HydroTac® provided a very effective way of treating a severe and painful chronic wound with an exposed tendon to the forefoot:

**Conflict of Interest:** Supported by Hartmann

**References:** Geiger SE, Deigni OA, Watson JT, Kraemer BA. Management of Open Distal Lower Extremity Wounds With Exposed Tendons Using Porcine Urinary Bladder Matrix. *Wounds*. 2016 Sep;28(9):306-316.

# An easy way to manage superficial second degree burn in children

*F. Duteille, P. Ridel, P. Perrot*

*Burn center adults and children, CHU Nantes, France*

**Aim:** Second degree superficial burn are certainly the most common but the more painful burn encountered by medical staff.

Despite the fact that the prognosis of such type of burn are excellent the management could be difficult due to this important pain. Normally second degree superficial burn go forward complete healing within two weeks maximum. There are a lot of habits and protocols which are used in burn center, but they certainly don't change the healing time. The major problem the medical has to deal with is to reduce the pain until the burn heal.

**Methods:** We try to evaluate the role that can play HydroTac in the management of second degree burn. To be enrolled patient must have 2° degree superficial burn and must be seen between D0 and D3. The dressing was apply and change was realize 2 times a week until complete healing.

**Results:** We focus our study on children and evaluated the dressing on 20 patients. The mean age was 6,8 years old and the location were : trunk or back ( 9 cases), abdomen ( 4 cases), face (2 cases) , limb ( 5 cases) All the patient healed between D8 and D12. For children who where old enough to evaluate, all have the feeling of pain reduction just after HydroTac was apply. The dressing change was evaluated as unpainful in all cases. Nurses appreciated the dressing because it reduce the need for change, make the management of such type of burn more easy and ensure a good evolution of the burn.

**Conclusion:** Finally HydroTac appear to be useful in the management of second degree superficial burn by reducing the pain and the number of dressing change

**Clinical relevance:** This is a new way to manage superficial second degree burn by reducing the need for dressing change. Dressing are easy to change, children are less painful and could be treated sometimes as outpatient.

# Treatment of ulcers with various etiologies

*Dr. Jacek Mikosiński*

*MIKOMED, Łódź, Poland*

**Introduction:** Ulcers have various etiologies. Most frequent are venous ulcers. Very often, however, these patients have diabetes and ulcers of such mixed etiologies are the most difficult to treat. In the described case, there was an additional problem associated with bleeding from the ulcer, which was difficult to control.

**Case description:** Female patient 86 years, height 162 cm, weight 68 kg, BMI 25.91 with chronic venous insufficiency reported to the clinic in 2010 due to ulcer on the shin. Since then, the ulcers have occurred several times with periods of remission lasting few year. At present, in August 2016, a new ulcer of 6.2x 3.5 cm in size occurred on right leg in the area of ankle. It was concluded the patient suffers also from atrial fibrillation (treated with Xarelto and Polocard), diabetes, hypercholesterolemia. The USG-D study revealed full-length venous insufficiency. Arterial system was not blocked. ABI 0.85. Initially the patient was treated with Bactigras and HydroClean plus. Once the ulcer was cleaned with 70% granular ulceration and 30% of fibrosis, the patient was qualified for HydroTac. On the 28th day of treatment there was bleeding from the ulcer during the change of dressing in the clinic. Bleeding so strong that it was necessary to put on stitches and apply the Kaltostat dressing. The anticoagulation drugs Xarelto, Polocard and Agapurin have been discontinued. Low molecular weight heparin was included. A compression knee socks were applied, 3 degree compression with an additional compression sponge. The wound was checked after two days and the HydroTac dressings were applied again. After 14 days stitches were removed, treatment with HydroTac was continued. At present (ie after 114 days of treatment) the ulcer is almost healed, its current size is 0.5 cm<sup>2</sup>.

**Conclusion:** HydroTac has proven to be a good dressing for the treatment of moderate granulomatous ulcers in combination with pharmacological treatment and proper compression therapy.

It is also important to systematically clean the wounds in the clinic and dressing instructions given by the nurse to the patient.

Wound cleaning in case of taking anticoagulation medication must be very delicate and should be done only in a surgical room because an adverse reaction requiring immediate stitching might occur.

**Clinical relevance:** The more often the patient comes to the clinic, the faster the healing of the ulcer. The key role in healing ulceration is professional, systematic cleaning of the wound.



# Wound management is everyone's concern

*Dr. Emmanuelle Candas, Dept of Geriatrics*

*Sainte Périné Hospital, Paris, France*

Whether we are a nurse, doctor, caregiver or surgeon, it forms part of our everyday life! Whether we practice in or out of a hospital, in the private or public sector, this management requires each of us to have skills when it comes to wound healing.

The principle of wound healing in a humid environment, established in 1963 by Dr Winter, is recognised as the foundation of good wound management.

In the elderly, there exist multiple intrinsic factors that affect and delay the natural healing process, making its management complex

In fact, it calls for even more attentive treatment due to the context of multiple pathologies, which characterises this population, and could be an obstacle to expected wound healing.

The cause of the wound will require essential general management measures, without which, no wound healing will be possible.

The choice of local treatment will also be paramount to encourage healing.

The concept suggested by Hartmann laboratory meets the requirements for wound healing through dynamic, "calibrated" hydration of the wound which is more closely adapted to the wound's needs, depending on the exudative nature and the stage of development.

To remove slough and necrotic tissue in the cleansing phase, the rapid autolytic action of the Hydroclean dressing makes it possible to avoid mechanical debridement which is often complex, both in terms of the health care professionals' time due to the elderly patients' fragile state of health and particularly when they present higher function disorders making the procedure difficult.

At the expected stage of granulation and epithelialisation, Hydrotac dressing encourages healing by maintaining this balanced state of hydration, a factor promoting keratinocyte migration.

The patient's comfort is preserved at each healing stage through rapid and painless treatments which contribute to the quality of secondary intention healing.

Using the principle of dynamic hydration helps elderly people regain cutaneous integrity which is so important to them, both physically and psychologically.

# Hydrotherapy a unique approach to treating foot ulcers in United Kingdom

*Dr. Paul Chadwick, Sam Haycocks*

*Salford Royal NHS Foundation Trust, United Kingdom*

**Aim:** To evaluate the impact of Hydro- Responsive Wound Dressings (HRWD) (Hydroclean plus and HydroTac) in wound bed preparation and promotion of healing in diabetic patients with wounds.

**Introduction:** Diabetic patients are susceptible to foot ulceration (DFU), healing in these wounds is compromised by the underlying pathology (Game and Jeffcoate, 2016; Clokie et al., 2017). This series of Case Studies shows how Hydro Responsive Wound Dressing – HRWDs (Hydroclean plus and/or HydroTac) had a positive impact on patients with a cross-section of wounds in which their healing was compromised by diabetes.

**Methods:** The study was undertaken at the Salford Royal (NHS) Foundation Trust, in the Podiatry department. Patients undergoing routine treatment for their wounds, but specifically in need of removal of devitalised tissue (eg slough) were entered into the evaluation. Both qualitative and quantitative evaluation of the impact of HRWDs was undertaken. HydroClean plus was used to remove devitalised tissue and prepare the wound bed for the second phase, re-epithelialisation and healing. In some patients HydroTac was then used to enable healing progression.

**Results:** Ten patients with wounds associated with diabetes (eg diabetic foot ulcers, post-surgical dehisced and post-amputation wounds) were treated with HRWDs over a period of one month. The results of this study show that Hydroclean plus over the course of the treatment effectively and rapidly removed the majority of the devitalised tissue in all of the patients thus enabling good wound bed preparation in terms of the presence of granulation tissue and supporting healing. In one patient with dehisced surgical wounds subsequent treatment with HydroTac enabled rapid re-epithelialisation and healing thus negating the need for amputation.

**Conclusion:** Hydroclean plus rapidly and painlessly enabled debridement of devascularised tissue, supporting wound bed preparation. The use of HydroTac in some instances promoted a rapid healing response. Importantly the HydroTherapy concept using HydroClean® plus and HydroTac was effective in preventing further damage and amputation in potentially limb threatening cases.

**Clinical relevance:** Diabetic foot ulcers are difficult to heal and generally require debridement to remove devitalised tissue. In this study HRWDs (Hydroclean plus and hydroTac) successfully enabled treatment of DFUs, rapidly debriding and supporting healing respectively.

**Conflict of Interest:** Study supported by Hartmann Ltd.

## References:

- Clokie M, Greenway AL, Harding K, Jones NJ, Vedhara K, Game F, Dhatariya KK. New horizons in the understanding of the causes and management of diabetic foot disease: report from the 2017 Diabetes UK Annual Professional Conference Symposium. *Diabet Med.* 2017 Mar;34(3):305-315
- Game FL, Jeffcoate WJ. Dressing and Diabetic Foot Ulcers: A Current Review of the Evidence. *Plast Reconstr Surg.* 2016 Sep;138(3 Suppl):158S-64S.

# Evaluating unexpected clinical changes in moist therapy

*Dr. Tomas Kopal, M.D.*

*Dept. Of Dermatology, City hospital of Povazska Bystrica*

Recently, classical therapeutic approach to chronic wound often lead do some kind of damage of surrounding skin, either due to contact irritation or allergy or due to maceration. The amount of patients allergic to some kind o topical medication is huge and is estimated to be 30-60% of all patients with chronic wound. The moist therapy offers clear benefit in lower occurrence of contact allergy to particular product, however some sensitisation still exist and can cause some confusion when evaluating wounds. Especially the difference between microbial eczema and contact eczema can be unclear. Another topic is the maceration. Moist therapy usually does not cause maceration, however recognising another similar condition -the hyperhydration may sometimes cause problems. The proper evaluation of wound surrounding is crucial, as it implicates necessary changes in therapy.

Clinical relevance: Compared to laboratory findings, clinical examination stays the most important way of evaluating chronic wound. Thus the ability to recognize adverse or other unexpected events in healing stays an important skill of physicians and nurses in daily practice.

Acknowledgements: Many thanks for information support to colleagues in Hartmann company

Conflict of Interest: External consultant of Hartmann company

# HydroTherapy in the management of postoperative diabetic foot wounds

*Dr. Eduard Catrina, General surgeon*

*Cantacuzino Hospital, senior lecturer, University of Medicine and Pharmacy, Carol Davila, Bucharest*

**Introduction:** HydroTherapy, this new concept of treatment of chronic and poor-healing wounds, consists in using of two consecutively special wet dressings, is designed to enhanced the wound healing process. First of these dressings - Hydro Clean with its variants, HydroClean and HydroClean Plus, is indicated in necrotic and dry chronic wounds, to promote cleansing and removing of the bacteria and their toxins, which contaminated the surfaces of the open wounds and probably delay the rising of granulation tissue. The other dressing in this range, HydroTac is consists from 2 layers with dual role. The outer is a poliuretana layer, impermeable to water and resistant to aggressive bacteria, and in the same time absorbent for excessive exudate, keeping the wound clean and sterile; the inner layer is consist from a net of hydrogel, which main role is to keep the wet enviroment and to promote granulation and epitelization of the wound.

**Aim:** Facing every day with a lot of diabetic foot infection, which require surgery in almost all cases, we have to deal with a lot of large and infected postoperative wounds in both neuropathic and arteriopathic patients. Each of these acute postoperative wounds needs a lot of resources, human and material, especially when the dressing is changed every day. On the other hand, diabetic background, by its characteristic immunodeficiency and micro and macroangiopathy, tend to favor infection and to slow down the process of granulation in acute open wound. As a result, we try to adjust the indication of HydroTherapy, sliding their use from chronic to acute diabetic wounds.

**Conclusion:** In our paper, we present our experience with HydroClean and HydroTac dressings in management of diabetic postoperative wound, from the very beginning until full granulation either to promote simple epithelization or, in cases of large soft tissue defects, to allow covering by split free skin. The results depends on vascularization, even the tissue from the bottom of the wound but also they are influenced by the germs involved in suppurative process.

# Extensive multifocal pressure ulcers in a young female patient bedridden due to multiple sclerosis: a case study.

Dr. Marcin Malka, Dr. Bartosz Ziemięcki, Agnieszka Wołowicz

PODOS Wound Care Clinic, Warsaw, Poland

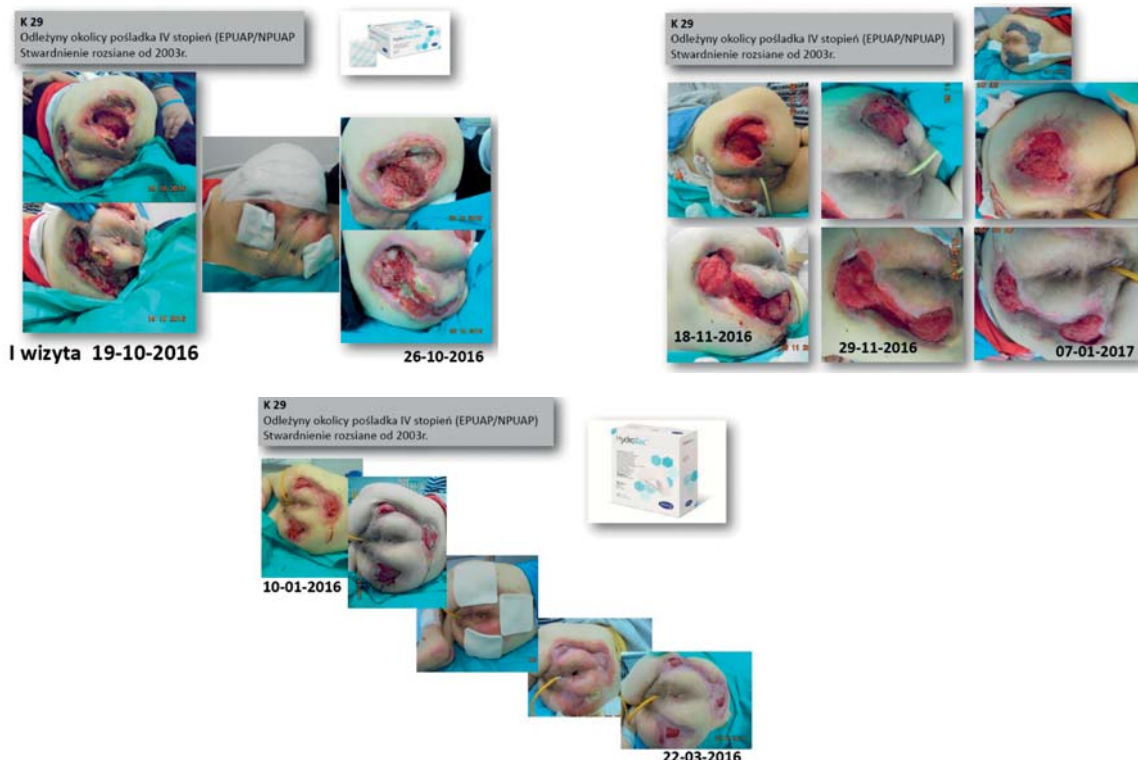
**Introduction:** Multiple sclerosis (MS) is a chronic inflammation-driven demyelinating disease with multifocal damage to the nervous tissue. MS is common cause of disability among young people.

**Case description:** A 29-year old female patient, suffering from MS since 2003, came to our clinic due to expanding pressure ulcers (PU) located in the sacral-ischial area. Body of the right ischium was present in the wound cavity. She also had PU of the left calf and left knee joint with leakage of synovial fluid and PU of the right elbow joint and right foot. Main causes for the development and exacerbation of the PU were identified as: lack of appropriate prophylaxis, patient malnutrition, and inadequate removal of the necrotic tissue from the wound cavity. The following multidisciplinary care was initiated. The family was educated on the most appropriate preventative care. Patient's diet was modified. Necrotic tissue was removed from the ulcers located on the buttocks and autolytic dressings (HydroClean Plus cavity and HydroClean Plus) were applied to the wounds. The same procedure was followed during subsequent visits until the necrotic tissue was entirely eliminated from the wound cavities. Further treatment of this area involved the introduction of negative-pressure wound therapy in order to connect the multifocal ulcers of the buttocks into one system. This part of the treatment was considered successful when granulation tissue developed in the wounds. Next, treatment with foam dressings with a hydrogel layer in direct contact with the wound (HydroTac) was introduced. The use of this dressing was planned until the wounds were completely healed.

**Conclusions:** Consistent use of causal therapy and HydroTherapy in the treatment of PU in a young patient with MS allowed gradual healing of extensive wounds.

**Clinical relevance:** Appropriate multidisciplinary care allows successful treatment of extensive PU.

**References:** Prevention and Treatment of Pressure Ulcers. Clinical Practice Guideline 2014



# Clinical experience in a case series on how Hydro Responsive Wound Dressings(\*) are used in the treatment of hard-to heal wounds

*Frans Meuleneire, Wound Expert*

*Wondzorg Hillegem, Belgium*

**Aim:** This series of case studies will exemplify the challenges of slough and necrotic tissue that necessitates removal in order that healing may occur. The wounds treated with the Hydro-Responsive Wound Dressings(\*) highlights the dressings ability to enable epithelialisation and support the wounds to complete healing.

**Methods:** Based on 10 case studies we have observed the effect of the Hydro-Responsive Wound Dressings(\*) on sloughy and necrotic wounds. Photographs will illustrate the different aspects of the effect due to our dressing choice.

**Results:** The Hydro-Responsive Wound Dressings(\*) had positive outcomes in every phase of the woundhealing process. In necrotic wounds, the autolytic debridement was accelerated. As soon as we obtained a granulation phase, the wound cavity was significantly decreasing. We could use these dressings in critical colonised and moderate infected wounds, where we observed a return to the bacterial balance.

In the end phase of the woundhealing, the epithelialisation was not disturbed because the dressings created an ideal moist environment without negative effects on the surrounding skin.

**Conclusion:** Our clinical experience in this series of case studies with HydroTherapy(\*) demonstrates why the products are first choice indication for effective cleansing, debridement and desloughing.

They provide an optimal moist wound environment which is essential for advanced wound healing

(\*) HydroClean plus followed by HydroTac

# Simplifying wound dressing selection for residential aged care nurses

Tabatha Rando<sup>1</sup>, Ai Choo Kang<sup>2</sup>, Jo Boylan<sup>2</sup>, Anthony Dyer<sup>1</sup>

1) Wound Management Innovation CRC

2) Southern Cross Care (SA/NT), (Adelaide, Australia)

**Aim:** To demonstrate the effectiveness of a simplified dressing selection protocol for nurses in residential aged care facilities (RACFs).

**Methods:** The study is conducted in 4 phases:

- 1) Identifying current practice through baseline measurement, cost analysis of existing wound dressing products and feedback from staff focus groups.
- 2) Providing wound management and the simplified wound management protocol staff education
- 3) Evaluating the new wound care products and protocol with residents and staff
  - For all skin tears
  - For other chronic/pressure wounds assessed as suitable by a Wound Management Nurse Practitioner including a list of where the simplified protocol is not appropriate
  - Collect and evaluate data
- 4) Undertaking post-intervention data analysis and reporting

**Results:** At the time of abstract submission more than 60 residents with wounds are being assessed through prospective data collection and 40 staff involved in baseline focus group data collection. Results are not yet available but will be presented.

**Discussion:** Wound management incorporates a complex combination of aetiologies, presentations, assessment skills, treatment options and wound dressing selections. A clinical setting with high presentation of wounds and need for wound management is RACF. However, RACF nurses need to be generalists and few have specialist wound expertise. Furthermore, there is a plethora of choice and number of wound dressings available to RACF nurses and product selection can be difficult and confusing. There is currently a gap between wound care needs, best practice management, staff capacity and competency in aged care.

Improving the confidence and wound management skills of aged care nurses working in RACFs through education and protocols is essential for improved resident wound outcomes. The introduction of a simplified wound dressing protocol where the majority of basic wound management needs are met is needed and identification of when specialist management is required could potentially reduce costs and suffering. It is expected that residents' satisfaction and wound outcomes will be known and recommendations for implementation of a simplified wound management protocol in RACFs will be identified.

**Conflict of Interest:** Support for this study has been provided by both organisations of this research group. Paul Hartmann Pty Ltd (Australia) has provided product and training support as unrestricted support.